



A Pregnant Woman with Hypertension at 36-Week Gestation

Parmar MS*

Department of Nephrology, Laurentian & Lakehead Universities, Canada

Abstract

Hypertension is the most common medical problem encountered during pregnancy. A case based approach is used to discuss differential diagnosis of hypertension during pregnancy. Pheochromocytoma is a rare but an important cause of hypertension during pregnancy because of its high morbidity and mortality to both the mother and the fetus. High index of suspicion is important to diagnose and manage such patients appropriately.

Keywords: Hypertension; Pregnancy; Pheochromocytoma; Preeclampsia; Eclampsia

Case Presentation

A 33-year old woman presented at 36-weeks gestation with spontaneous episodes of feeling anxious with headache, chest tightness and flushing lasting for 15 minutes to couple of hours. These episodes are associated with marked hypertension with systolic blood pressure of up to 190 mmHg. The current pregnancy had been uneventful until now, and she delivered by C-section her previous two full-term pregnancies. She had no history of hypertension. Because of her previous C-sections, a c-section was planned at 38-weeks. She was on no medications except for prenatal vitamins. She doesn't smoke and denied alcohol use. She had no history of hypertension.

Physical examination was unremarkable except for gravid uterus. Heart sounds were normal. The blood pressure most of the times was between 100-110/70 mmHg except for during the "episodes" when her blood pressure would rise to 190/110 mmHg with heart rate of 70 to 90 beats per minute. There was no peripheral edema. Her reflexes were normal.

Her hemoglobin was 118 g/L and BUN, serum creatinine, serum potassium, thyroid stimulating hormone were normal, urinalysis is negative for protein, and electrocardiogram was normal.

OPEN ACCESS

*Correspondence:

Malvinder S. Parmar, Department of Nephrology, Northern Ontario School of Medicine, Laurentian & Lakehead Universities, Sudbury & Thunder Bay, Ontario, Canada,

E-mail: atbeat@ntl.sympatico.ca

Received Date: 04 May 2016

Accepted Date: 28 Oct 2016

Published Date: 15 Nov 2016

Citation:

Parmar MS. A Pregnant Woman with Hypertension at 36-Week Gestation. *Remed Open Access*. 2016; 1: 1024.

Copyright © 2016 Parmar MS. This is an open access article distributed under the Creative Commons Attribution License, which permits unrestricted use, distribution, and reproduction in any medium, provided the original work is properly cited.

Question 1: What is your diagnosis?

- Gestational hypertension
- Preeclampsia-eclampsia
- Pre-existing (chronic) hypertension
- Pheochromocytoma

Answer: (D) Hypertension complicates 2-3% of pregnancies and is the most common medical problem encountered during pregnancy. Hypertension during pregnancy may be secondary to chronic (pre-existing) hypertension, gestational hypertension or preeclampsia/eclampsia and rarely could be secondary to an adrenal pathology. Chronic hypertension is defined as blood pressure exceeding 140/90 mmHg either before pregnancy or before 20 weeks of gestation. Elevation of blood pressure after 20 weeks of gestation may be gestational hypertension but mandates exclusion of preeclampsia. Preeclampsia occurs in about 5% of all pregnancies, with up to 10% of first pregnancies and in 20-25% of women with chronic (pre-existing) hypertension or underlying kidney disease.

The symptoms of episodic severe hypertension associated with headache, palpitations, flushing and chest tightness raises the possibility of catecholamine induced pathology, like pheochromocytoma, and plasma free catecholamines and urinary catecholamines were requested. She was admitted for ongoing monitoring and further assessment.

The plasma free catecholamines levels showed elevated norepinephrine level of 4.0 nmol/L (0.8-3.4) and normal epinephrine level of 0.4 nmol/L (<0.8). The 24-hr urine revealed markedly elevated epinephrine of 1894 [<120 nmol/d], norepinephrine of 1401 [<500 nmol/d], dopamine of 4023 [<3200

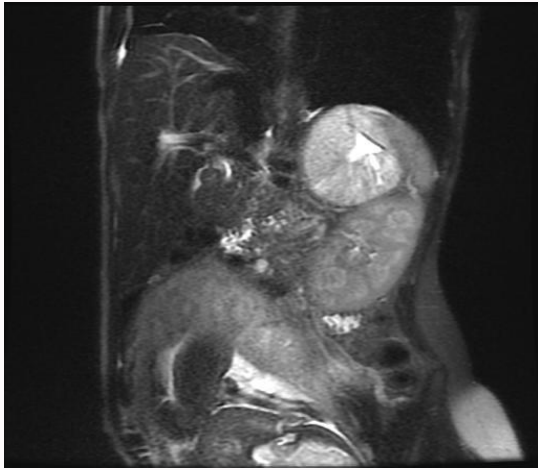


Figure 1: MRI - Coronal T2 single shot shows a 6.7x6.7x6.3 cm T2 hyperintense mass with a central area of increased T2 hyperintensity, in the left adrenal fossa. 135x135 mm (96 x 96 DPI).

nmol/d] and VMA of 204 [6-36 umol/d], confirming catecholamine excess either from adrenal chromaffin cells (pheochromocytoma) or extra-adrenal paraganglia (paraganglioma).

An abdominal ultrasound showed a 7-8 cm mass in left adrenal gland that was also confirmed by MRI (Figure 1), consistent with pheochromocytoma.

Question 2: How will you manage blood pressure and her current pregnancy?

- Immediate delivery
- Bed rest
- Alpha-blockade
- Beta-blockade
- Methyldopa

Answer: (c) She was started on doxazosin 1 mg twice a day with plan to increase as tolerated to 10 mg a day and was transferred to high-risk pregnancy management center, where after increasing the dose of doxazosin, she underwent C-section under the supervision of a multidisciplinary team comprising of obstetrician, intensivist, endocrinologist and anesthesiologists. Few months later, she underwent laparoscopic adrenalectomy.

Discussion

Pheochromocytoma is a rare, with a reported incidence of <0.2 per 10,000 pregnancies [1], but important cause of hypertension in pregnancy because of its high morbidity and mortality, of up to 58%, to both the mother and the fetus. Most adrenal tumors produce both epinephrine and norepinephrine or predominantly epinephrine, whereas most extra-adrenal tumors produce predominantly norepinephrine. Norepinephrine increases peripheral vascular

resistance resulting in increase in systolic and diastolic blood pressure. Epinephrine increases cardiac output and systolic blood pressure. Epinephrine producing tumors often produce episodic symptoms whereas norepinephrine symptoms are often associated with continuous (non-episodic) symptoms [2].

Several mechanisms can unmask pheochromocytoma during pregnancy and include increase in intra-abdominal pressure, fetal movement, uterine contractions, and process of delivery, surgical intervention and even general anesthesia.

The 24-hr urine collection for catecholamines is recommended in pregnant patients and these levels are not affected by pregnancy [3]. The plasma catecholamines have a specificity of 85-89% with a false positive rate of 11-15%.

The primary goal of therapy is to prevent hypertensive crisis that may result in fetal or maternal demise. Therapy with α -blockade is must and should be started as soon as the diagnosis is established and ideally should be given for 10-14 days before delivery or surgery [4]. The drug of choice is phenoxybenzamine (often difficult to get), and doxazosin (selective α_1 blocker) have been used lately with success [5]. However, as doxazosin is a competitive antagonist, it can be displaced by high-levels of endogenous catecholamines. Unopposed β -blockade should be avoided, as this precipitates hypertensive crisis and should only be used after adequate α -blockade to control tachycardia. Methyldopa, an agent commonly used to treat hypertension during pregnancy should be avoided as it may worsen symptoms of pheochromocytoma [6].

Surgery is the definitive treatment for pheochromocytoma. In early pregnancy tumor removal is recommended after optimal medical management, but after 24-weeks of gestation surgical removal is recommended after an elective cesarean section. A retrospective review showed that vaginal delivery has higher mortality (31%) compared to cesarean section (19%) [6].

References

- Dugas G, Fuller J, Singh S, Watson J. Pheochromocytoma and pregnancy: a case report and review of anesthetic management. *Can J Anaesth.* 2004; 51: 134-138.
- Pacak K. Preoperative management of the pheochromocytoma patient. *J Clin Endocrinol Metab.* 2007; 92: 4069-4079.
- Kudva, YC, Sawka AM, Young WF Jr. Clinical review 164: The laboratory diagnosis of adrenal pheochromocytoma: the Mayo Clinic experience. *J Clin Endocrinol Metab.* 2003; 88: 4533-4539.
- Kinney MA, Narr BJ, Warner MA. Perioperative management of pheochromocytoma. *J Cardiothorac Vasc Anesth.* 2002; 16: 359-369.
- Kalra JK, Jain V, Bagga R, Gopalan S, Bhansali AK, Behera A, et al. Pheochromocytoma associated with pregnancy. *J Obstet Gynaecol Res.* 2003; 29: 305-308.
- Junglee N, Harries SE, Davies N, Scott-Coombes D, Scanlon MF, Rees DA. Pheochromocytoma in Pregnancy: When is Operative Intervention Indicated? *J Womens Health (Larchmt).* 2007; 16: 1362-1365.