



# A Case of Dental Implant Screwdriver Aspiration

Kutluhan F and Şahin F\*

Department of Chest Diseases, Yedikule Chest Diseases & Thoracic Surgery Training and Research Hospital, Turkey

## Abstract

A 51-year-old male patient was admitted to our emergency room with an intense chest pain on inspiration and shortness of breath. It turned out that, 6 hours before his complaints started, a dental implant screwdriver had been integrated in his upper palate. Posteroanterior chest X-ray and thoracic computed tomography showed the implant screwdriver at the entrance of the right lower lobe. The location of the instrument was confirmed by fiberoptic bronchoscopy and it was removed successfully without causing any complications. Foreign body aspirations should always be suspected in patients who have new onset of pulmonary symptoms even without any history of aspiration especially after dental procedures.

**Keywords:** Foreign Body aspiration; Dental implant; Bronchoscopy

## Introduction

Tracheobronchial foreign body aspirations may occur in all age groups. It is a very serious and critical problem. It may cause chronic and irreversible lung injury and may even be a life-threatening medical situation. As a rare event in the literature, foreign body aspiration is a well recognised complication of routine dental care. A wide variety of aspirated foreign bodies have been reported from teeth and restorative materials to instruments, for example dental screwdriver aspiration [1-4]. High clinical suspicion is necessary for diagnosis and early diagnosis is key to the prevention of complications. For evaluation and removal of foreign bodies' flexible bronchoscope is the usual initial diagnostic tool.

## Case Presentation

A 51-year-old male patient presented to a private dentist to have an implant placed in his upper palate. A dental implant screwdriver was integrated uneventfully. 5 hours after the procedure, the patient felt an object dropped into his oropharynx and was swallowed without any difficulty. He called his dentist and he was told to refer to an emergency in case of any symptoms. In 1 hour, he started to feel an intense chest pain on inspiration and shortness of breath and was admitted to our emergency room. At the physical examination, there was a reduction in breath sounds on the right lower area of the thorax. According to the clinical findings: SpO<sub>2</sub>: 96%, respiratory rate: 20/min, pulse: 78/min, blood pressure: 125/75 mmHg. Laboratory findings showed normal results except for white blood cell (WBC): 10,200 K/mm<sup>3</sup>. On posteroanterior chest radiography was an impacted radiopaque dental instrument could be observed in the right lower lobe bronchus (Figure 1) and it was confirmed with thoracic computed tomography (Figure 2). In fiberoptic bronchoscopy, the implant screwdriver was identified at the entrance of the right lower bronchus (Figure 3). It was removed successfully without damaging the surrounding tissues (Figure 4). After the bronchoscopy, the symptoms of the patient were resolved and his physical examination findings disappeared. He was discharged on the same day with no complications or sequelae.

## Discussion

Tracheobronchial foreign body aspirations may occur in all age groups. It is a serious and potentially life-threatening emergency [5-7]. Diagnosis can be based on a detailed history, physical examination and the radiological findings of the patient. Symptoms of acute developing aspirations are mostly coughing, choking, shortness of breath, chest pain and cyanosis [4,8]. Depending on the size, shape and flexibility of the object, it may stay asymptomatic or may cause severe respiratory insufficiency [4,7]. Location of the foreign body in the airway is associated with the anatomical structure of the tracheobronchial tree and the posture of the individual during aspiration [9]. Generally foreign bodies lodge in the right main bronchus and lower lobe bronchi, as the right main bronchus is more vertically aligned and its diameter is wider than the left main bronchus [10]. In our

## OPEN ACCESS

### \*Correspondence:

Fusun Şahin, Department of Chest Diseases, Yedikule Chest Diseases and Thoracic Surgery Training and Research Hospital, İstanbul, Turkey,  
Tel: +90 532 7112893;

E-mail: fusunshahin19700@hotmail.com

Received Date: 11 Jul 2016

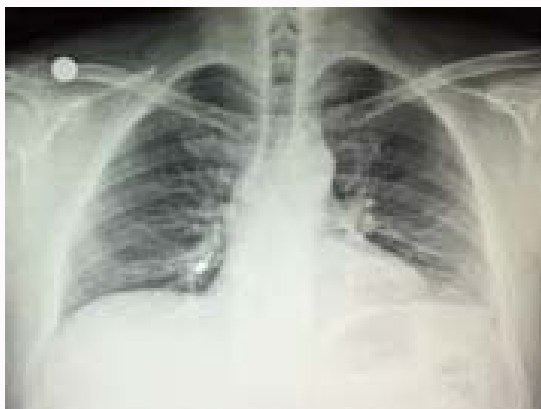Accepted Date: 24 Aug 2016

Published Date: 16 Sep 2016

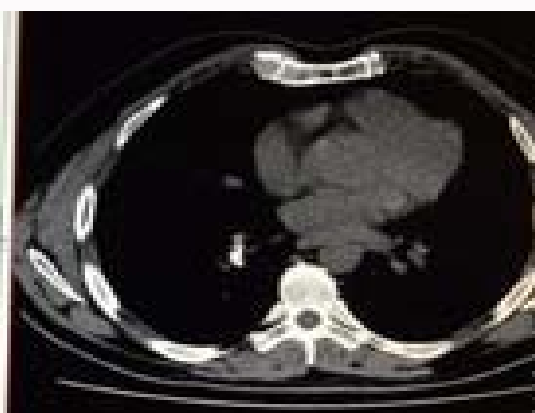### Citation:

Kutluhan F, Şahin F. A Case of Dental Implant Screwdriver Aspiration. *Remedy Open Access*. 2016; 1: 1018.

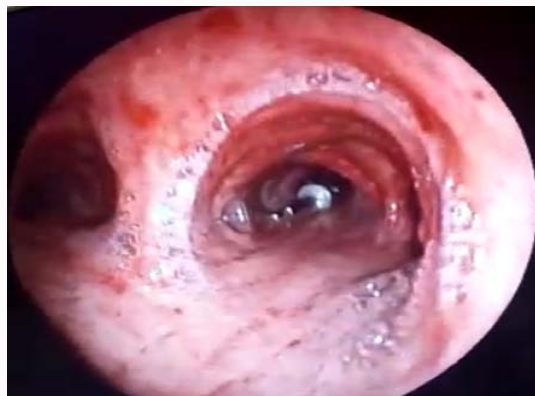**Copyright** © 2016 Şahin F. This is an open access article distributed under the Creative Commons Attribution License, which permits unrestricted use, distribution, and reproduction in any medium, provided the original work is properly cited.



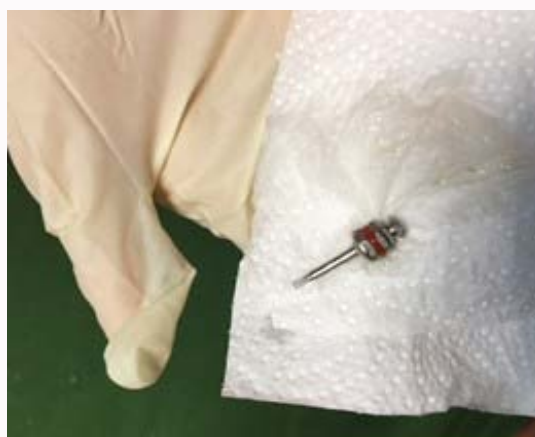
**Figure 1:** Posteroanterior chest radiograph showing radiopaque dental instrument located in the right lower lobe bronchus.



**Figure 2:** Thoracic computed tomography showing dental instrument located at the entrance of the right lower lobe bronchus.



**Figure 3:** Location of the instrument visualized by fiberoptic bronchoscopy.



**Figure 4:** Removed dental implant screwdriver.

case it was detected at the entrance of the right lower lobe bronchus.

Chronic symptoms with recurrent infections might occur with delayed extraction, or the patient may remain asymptomatic. Mostly the aspirated object is food but a broad spectrum of aspirated items has been documented as seeds, nuts, bone fragments, nails, small toys, coins, pins, medical instrument fragments and dental appliances [11-13]. As a rarely seen but a well recognised complication of routine dental care, a wide variety of aspirated foreign bodies have been reported from teeth and restorative materials to instruments [4,8,14-17]. Aspiration or ingestion of instruments and material can occur in any dental procedure. The incidence increases when preventive methods are not used. These steps include using rubber dam whenever possible, tethering any small instrument with a ligature and placing gauze screens across the oropharynx of the conscious or sedated patient [18]. For our case, it was a dental implant screwdriver.

After the instrument reaches the oropharynx it is important to determine whether the foreign body is located in the gastrointestinal tract or in the respiratory system. Radiographic examination is mandatory for the differential diagnosis of location, nature and size of the foreign body. This should begin with the acquisition of anteroposterior and lateral chest, lateral neck and supine abdominal radiographs to complete the evaluation from the nasopharynx to the rectum [19,20].

Generally chest X-rays show the foreign body. If the foreign

body is radiopaque, it can easily be detected by posteroanterior chest X-rays [19,20]. In order to correctly locate and determine the size of the foreign body thoracic computed tomography should also be obtained [20]. In our case, the diagnosis was made with chest X-ray and thoracic computed tomography.

As diagnosed, removal of the foreign bodies should be performed as soon as possible. Persistence of the foreign body for more than 24 hours is associated with increased morbidity and a longer hospital stay [6]. Bronchoscopy is the treatment of choice for removing inhaled foreign body but if the foreign body cannot be removed by flexible bronchoscopy rigid bronchoscopy under general anesthesia can be used as an appropriate alternative treatment option [21]. For our case, the foreign body was successfully removed by fiberoptic bronchoscopy.

## Conclusion

Foreign body aspirations are serious and potentially fatal problems. Early diagnosis is the key to the prevention of complications. A detailed medical history, physical examination and radiological evaluation are mandatory for early diagnosis. Especially, the patients who have sudden onset of pulmonary symptoms should be taken seriously by dentists. To avoid accidental aspiration or ingestion of foreign bodies' prevention is of the highest importance. When indicated, removal of the foreign bodies should be performed as soon as possible and early removal by bronchoscopy is the ideal procedure to reduce morbidity.

## References

- Kim A, Ahn KM. Endoscopic removal of an aspirated healing abutment and screwdriver under conscious sedation. *Implant Dent.* 2014; 23: 250-252.
- Deliberador TM, Marengo G, Scaratti R, Giovanini AF, Zielak JC, Baratto Filho F. Accidental aspiration in a patient with Parkinson's disease during implant-supported prosthesis construction: a case report. *Spec Care Dentist.* 2011; 31: 156-161.
- Bergermann M, Donald PJ, aWengen DF. Screwdriver aspiration. A complication of dental implant placement. *Int J Oral Maxillofac Surg.* 1992; 21: 339-341.
- Pingarrón Martín L, Morán Soto MJ, Sánchez Burgos R, Burgueño García M. Bronchial Impaction of an Implant Screwdriver after Accidental Aspiration: Report of a Case and Revision of the Literature. *Oral Maxillofac Surg.* 2010; 14: 43-47.
- Baharloo F, Veyckemans F, Francis C, Bietlot MP, Rodenstein DO. Tracheobronchial foreign bodies: presentation and management in children and adults. *Chest.* 1999; 115: 1357-1362.
- Zitzmann NU, Elsasser S, Fried R, Marinello CP. Foreign body ingestion and aspiration. *Oral Surg Oral Med Oral Pathol Oral Radiol Endod.* 1999; 88: 657-660.
- Başoğlu A, Çelik B, Demircan S, Akdag A O, Gündođdu B, Kaya S, et al. Erişkinlerde Trakeobronşiyal Yabancı cisimler. *Journal of Experimental and Clinical Medicine.* 2004; 21: 117-122.
- Umesan UK, Chua KL, Balakrishnan P. Prevention and Management of Accidental Foreign Body Ingestion and Aspiration In Orthodontic Practice. *Ther Clin Risk Manag.* 2012; 8: 245-252.
- Rafanan AL, Mehta AC. Adult airway foreign body removal. What's new? *Clin Chest Med.* 2001; 22: 319-330.
- Dikensoy O, Usalan C, Filiz A. Foreign body aspiration: clinical utility of flexible bronchoscopy. *Postgrad Med J.* 2002; 78: 399-403.
- Kısacık E, Gülhan E, Sırmalı M, Sarıca E, Türüt H, Karasu S, et al. Trakeobronşiyal Yabancı Cisim Aspirasyonları: 261 Olgunun Analizi. *Solunum Hastalıkları.* 2004; 15: 86-91.
- Yorgancılar CD, Çelik A, Karakurt Ö, Demircan S. Trakeobronşiyal Yabancı Cisim Aspirasyonları; 25 Olgunun Analizi, İsmail Cüneyt Kurul. *Gazi Tıp Dergisi/Gazi Medical Journal.* 2009; 20: 13-16.
- Debeljak A, Šorli J, Musić E, Kecelj P. Bronchoscopic removal of foreign bodies in adults: experience with 62 patients from 1974-1998. *Version of Record online.* 1999; 14: 792-795.
- Cameron SM, Whitlock WL, Tabor MS. Foreign body aspiration in dentistry: a review. *J Am Dent Assoc.* 1996; 127: 1224-1229.
- Atilla N, Arpag H, Atilla S, Irmak I, Beyaz A. "A Case of Dental Prosthesis Aspiration in a Patient with Tracheostomy." *Respiratory Case Reports.* 2016; 5: 1-4.
- Günay Ş, Erbaş AE, Arun F, Klinigi GC, Klinigi AR, Hastanesi OD, et al. An Adult Patient with Pneumonia Due to Aspiration of Dental Prosthesis. *Journal of Clinical and Analytical Medicine.* 2015; 6: 100-102.
- Kaya SU, Topçu S. Prosthetic teeth aspiration: As bronchial asthma. *Türkiye Klinikleri J Allergy-Asthma.* 2000; 2: 168-170.
- De Souza JG, Schuldt Filho G, Pereira Neto AR, Lyra HF Jr, Bianchini MA, Cardoso AC. Accident in implant dentistry: involuntary screwdriver ingestion during surgical procedure. A clinical report. *J Prosthodont.* 2012; 21: 191-193.
- Kuo SC, Chen YL. Accidental swallowing of an endodontic file. *Int Endod J.* 2008; 41: 617-622.
- Mann R, Srinivasan B, Baker A. Managing aspiration. *British Dental Journal.* 2012; 212: 464-465.
- Donado Uña JR, De Miguel Poch E, Casado Lopez ME, Alfaro Abreu JJ. Tracheobronchial foreign body extraction with fiberoptic bronchoscopy in adults. *Arch Bronconeumol.* 1998; 34: 76-81.