



Isolated Bladder Neurofibroma: A Case Report and Review of Literature

Hosseini SZ¹, Alizadeh F^{2*} and Ghana'at F

¹Department of Urology, Tehran University of Medical Sciences, Iran

²Department of Urology, Isfahan University of Medical Sciences, Iran

Abstract

Neurofibroma, a benign tumor of the nerve sheath, is the result of an abnormal overgrowth of Schwann's cells and fibroblasts. This disorder is often seen in the context of hereditary neurofibromatosis (NF). Genitourinary (GU) tract involvement is rarely seen in NF, with fewer than 70 cases of bladder involvement being reported in the literature. We add another case in a 25-year-old female patient who came with dysuria. The tumor was evident as a filling defect in intravenous urography and was resected transurethrally. Pathologic examination revealed spindle cells with elongated vesicular nucleus and ill-defined cytoplasm, in edematous stroma and positive staining for S100 in immunohistochemistry. We also provide a literature review on this field.

Keywords: Neurofibroma; Bladder; Mass

Introduction

Neurofibromatosis was first introduced by Smith in 1849, and later described in details by von Recklinghausen [1].

Neurofibroma, a benign tumor of the nerve sheath, is the result of an abnormal overgrowth of Schwann's cells and fibroblasts. This disorder is often seen in the context of hereditary neurofibromatosis (NF) [2].

NF is an autosomal dominant disorder, with a prevalence of approximately 1 in 3000. Other lesions associated with this disorder are skin fold freckling, café-au-lait spots, cutaneous and oral plexiform neurofibromas, Lisch nodules, massive soft tissue neurofibromas, learning disability and malignant transformation of peripheral or central tumors. About half of all cases result from new mutations and are sporadic [3].

Genitourinary (GU) tract involvement is rarely seen in NF, with fewer than 70 cases of bladder involvement being reported in the literature [3]. Due to rarity of the entity, optimal management and follow-up plans have yet to be defined. We add another case and review the literature on this field.

Case Report

A 25-year-old female patient came with dysuria. Lab test results were normal except for a microscopic hematuria. GU ultrasound revealed a bladder mass with normal upper tract. This mass was seen as a filling defect on intravenous urogram (Figure 1). In the operation room, cystoscopy was performed that showed a 2 cm, pedunculated mass (Figure 2).

Then, transurethral resection of the mass was done, using a 22F monopolar resectoscope and sterile distilled water as the irrigant. The mass itself and a cut from its base that included the bladder wall muscle were sent for pathologic examination in separate containers.

Pathologic examination was done by a pathologist expert in GU pathology that reported a bladder neurofibroma. The tumor was composed of spindle cells with elongated vesicular nucleus and ill-defined cytoplasm, in edematous stroma in high power view (H&E X 100) (Figure 3). Immunohistochemical (IHC) staining against S100, showed positive nuclear staining in the tumor cells (X400) (Figure 4). There was no involvement of bladder wall musculature evident on microscopic examination.

OPEN ACCESS

*Correspondence:

Farshid Alizadeh, Department of Urology, Isfahan Kidney Transplantation Research Center, Al-Zahra Hospital, Isfahan University of Medical Sciences, Isfahan, Iran, Tel: +989133179509; Fax: +983136263383;

E-mail: f_alizadeh@med.mui.ac.ir

Received Date: 28 Jun 2016

Accepted Date: 29 Jul 2016

Published Date: 31 Jul 2016

Citation:

Hosseini SZ, Alizadeh F, Ghana'at I. Isolated Bladder Neurofibroma: A Case Report and Review of Literature. *Remed Open Access*. 2016; 1: 1012.

Copyright © 2016 Alizadeh F. This is an open access article distributed under the Creative Commons Attribution License, which permits unrestricted use, distribution, and reproduction in any medium, provided the original work is properly cited.

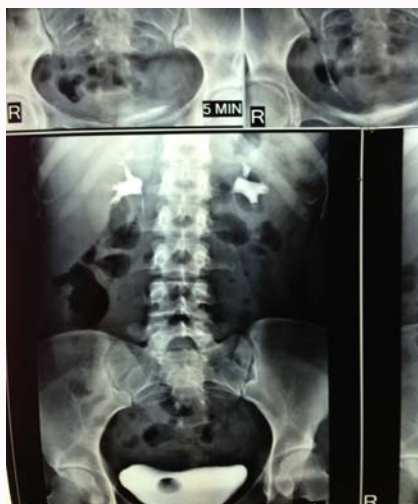

Figure 1: The bladder mass was seen as a filling defect.

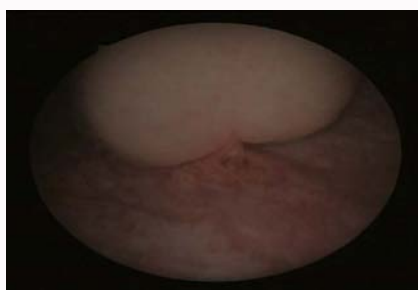


Figure 2: Pedunculated mass near the ureteral orifice.

Discussion

Bladder neurofibromas originate from nervous ganglia of the bladder wall. IHC techniques show positive staining for protein S-100 and type IV collagen [2].

When bladder involvement is in the setting of generalized disease, it affects males more commonly (ratio: 2.3/1) and the mean age is 17 years [4]. However, in reported cases of isolated bladder involvement, no sex preference is visible. Patients are usually young adults (age range: 6-52 years) [2-5].

The most common presenting symptoms are irritative lower urinary tract symptoms (LUTS) [2,3,5]. Other presentations include microscopic or gross hematuria [4,5], recurrent urinary tract infection and asymptomatic pelvic mass [2].

Our case had a pedunculated mass in her bladder. Others have reported diffuse polypoid lesions [3], an isolated lesion [2,3,5] and even mucosal erythema [5].

Other typical presentations of neurofibromatosis are rarely seen in patients with isolated bladder involvement.

Our patient has remained symptom-free after one year of follow-up. In the Cheng's series [5], however, development of atonic and neurogenic bladder and persistence of gross hematuria were reported that warrants long-term follow-up of all patients, including ours.

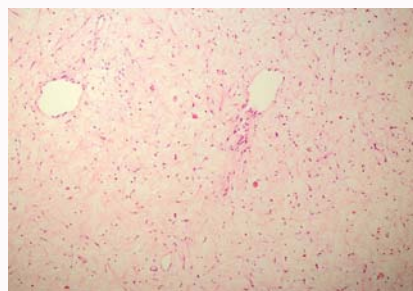


Figure 3: High power view of the tumor, composed of spindle cells with elongated vesicular nucleus and ill defined cytoplasm, in edematous stroma (H&E X 100).

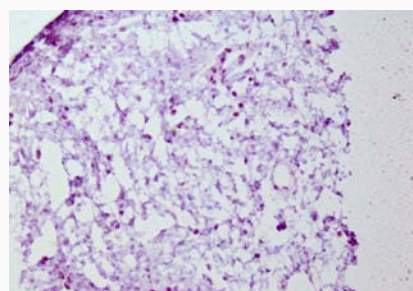


Figure 4: Immunohistochemical staining against S100, showing positive nuclear staining in the tumor cells (X400).

In isolated lesions, trans-urethral resection suffices, although more diffuse cases may need partial cystectomy [5].

No case of recurrence in isolated bladder involvement has been reported yet, that signifies the benign nature of this entity. However, malignant transformation has been reported in a few cases of bladder neurofibromas in the setting of generalized disease [5]. This finding necessitates long-term follow-up of all cases with isolated bladder involvement, as well.

References

1. Chakravarti A, Jones MA, Simon J. Neurofibromatosis involving the urinary bladder. *Int J Urol.* 2001; 8: 645-647.
2. Cabrera Castillo PM, Alonso y Gregorio S, Cansino Alcaide JR, Aguilera Basan A, De La Pena Barthel JJ. [Bladder neurofibroma: case report and bibliographic review]. *Arch EspUrol.* 2006; 59: 899-901.
3. Winfield HN, Catalona WJ. An isolated plexiform neurofibroma of the bladder. *J Urol* 1985; 134: 542-543.
4. Scheithauer BW, Santi M, Richter ER, Belman B, Rushing EJ. Diffuse ganglioneuromatosis and plexiform neurofibroma of the urinary bladder: report of a pediatric example and literature review. *Hum Pathol.* 2008; 39: 1708-1712.
5. Cheng L, Scheithauer BW, Leibovich BC, Ramnani DM, Cheville JC, Bostwick DG. Neurofibroma of the urinary bladder. *Cancer.* 1999; 86: 505-513.