



# A Novel use of Short Tandem Repeat DNA Analysis to Differentiate Persistent Versus New Ectopic Pregnancy Following Salpingostomy

Boonyasampant M<sup>1</sup>, Yau D<sup>1</sup>, Ramzan A<sup>2</sup>, Israel R<sup>2</sup>, Ward PM<sup>3</sup> and Shulman IA<sup>1\*</sup>

<sup>1</sup>Department of Pathology, University of Southern California Medical Center, USA

<sup>2</sup>Department of Obstetrics & Gynecology, Keck School of Medicine of USC, USA

<sup>3</sup>Molecular Pathology, Keck School of Medicine of USC, USA

## Abstract

Ectopic pregnancies treated conservatively by salpingostomy have a 3-20% risk of a persistent ectopic pregnancy. Follow-up serial serum human chorionic gonadotropin (hCG) levels are used to assess adequate treatment. Normalized levels indicate that the ectopic pregnancy has been adequately removed and the risk of persistent ectopic pregnancy is minimal. We report a patient with normalized hCG levels seven days after a salpingostomy for an ectopic pregnancy, who represented on day 38 after salpingostomy with a histology proven ectopic pregnancy in the same fallopian tube as the first. The possibility of a laboratory error with the day 8 hCG measurement and the possibility of a second independent ectopic pregnancy was investigated. Review of laboratory records ruled out an erroneous hCG measurement. Short tandem repeat (STR) DNA analysis, performed on macro-dissected formalin-fixed, paraffin-embedded tissue on both ectopic specimens, confirmed the ectopic pregnancy was persistent rather than two separate pregnancies. This is a rare case of a persistent ectopic pregnancy confirmed by STR analysis in a patient with a normalized hCG value after salpingostomy.

## OPEN ACCESS

### \*Correspondence:

Ira A. Shulman, Department of Pathology, University of Southern California, 1100 N. State Street, Room CT-A7E115, Los Angeles, CA 90033; USA,

E-mail: [ishulman@usc.edu](mailto:ishulman@usc.edu)

Received Date: 09 May 2016

Accepted Date: 03 Jun 2016

Published Date: 10 Jun 2016

### Citation:

Boonyasampant M, Yau D, Ramzan A, Israel R, Ward PM, Shulman IA. A Novel use of Short Tandem Repeat DNA Analysis to Differentiate Persistent Versus New Ectopic Pregnancy Following Salpingostomy. *Remed Open Access*. 2016; 1: 1008.

**Copyright** © 2016 Shulman IA. This is an open access article distributed under the Creative Commons Attribution License, which permits unrestricted use, distribution, and reproduction in any medium, provided the original work is properly cited.

**Keywords:** Persistent ectopic pregnancy;  $\beta$ -hCG; Salpingostomy; Short tandem repeat analysis

## Introduction

We report an ectopic pregnancy patient treated with salpingostomy. Despite normalized serum hCG post treatment, the patient developed a recurrent ectopic pregnancy confirmed by STR analysis.

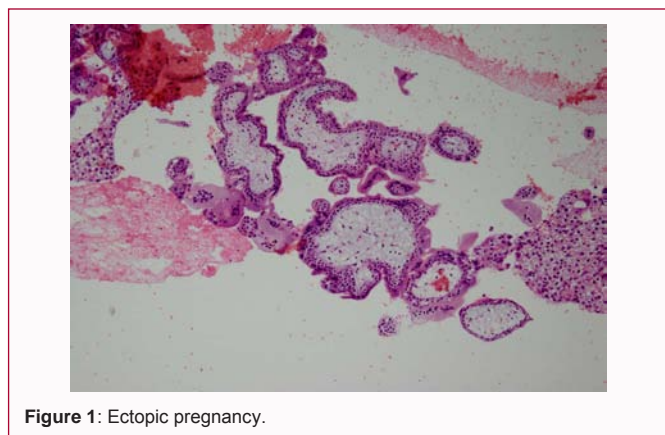
The patient is a 31 year old gravida 9, para 4, spontaneous abortion 4, who initially presented with a four day history of increasingly severe right lower abdominal pain. Her medical history was significant for asthma and endometriosis. Her last menstrual period was 21 days prior. Physical examination revealed stable vital signs with significant lower abdomen tenderness and guarding. A focused assessment with sonography for trauma (FAST) was positive with free fluid in the hepatorenal-recess. Labs were notable for a  $\beta$ -hCG of 571mIU/ml (Table 1). A transvaginal ultrasound demonstrated abundant free fluid in the pelvis and absence of an intrauterine gestational sac, raising concern for a ruptured ectopic pregnancy. The patient's hemoglobin dropped from 10 to 7 while being evaluated in the emergency department. An emergent exploratory laparotomy was performed, with surgical findings of 450mL of hemoperitoneum and an un-ruptured, ampullary ectopic gestation. The source of the bleeding was the fimbriated end of the right fallopian tube. There were no signs of endometriosis and the uterus and left adnexa were normal. A salpingostomy was performed with no complications. Tissue sample sent to pathology showed chorionic villi and fallopian tube mucosa confirming a tubal ectopic pregnancy (Figure 1). Depot medroxyprogesterone acetate was administered the next day and the patient was discharged.

On day 8 post-salpingostomy clinic visit, the serum hCG had normalized to 2 mIU/mL and her hemoglobin was stable at 11.7 g/dL. A transvaginal ultrasound revealed normal adnexa and no free fluid. At a clinic appointment 21 days after salpingostomy, the patient reported feeling well with no complaints. Serum hCG was not measured on this visit.

38 days post-salpingostomy, the patient returned to the emergency department complaining of diffuse, sharp abdominal pain that began after intercourse one day previously. Since the

**Table 1:** hCG, transvaginal ultrasound, surgical, and pathologic findings on days since first presentation.

Days since presentation	hCG (mIU/ml)	Transvaginal Ultrasound	Surgical findings	Pathology
1	571	Free fluid, no gestational sac	Salpingostomy: adnexal mass, right ampulla	Chorionic villi consistent with ectopic pregnancy
8	2	No adnexal mass	-	-
21	-	-	-	-
38	185	Adnexal mass, right ampulla	Salpingectomy: adnexal mass, right ampulla	Chorionic villi consistent with ectopic pregnancy



**Figure 1:** Ectopic pregnancy.

salpingostomy, she had experienced occasional vaginal spotting. Free fluid and an 8.6 cm complex mass located in the right adnexa were identified by transvaginal ultrasound. hCG levels had increased to 185mIU/ml (Table 1). Diagnostic laparoscopy revealed 900ml of hemoperitoneum and an enlarged, un-ruptured right fallopian tube with active bleeding from the fimbria. The left adnexa and uterus were unremarkable. A right salpingectomy was performed and the tissue, sent to surgical pathology, again showed chorionic villi and fallopian tube consistent with a tubal ectopic pregnancy (Figure 2).

**Materials and Method**

The two surgical pathology specimens were examined and one slide containing both fetal (chorionic villi) and maternal tissue was chosen from each case. Both specimens were differentially macro-dissected into fetal and maternal. DNA was isolated using the Maxwell FFPE DNA purification kit (Promega) as per the manufacturer's instructions. DNA concentration was quantified using the Nanodrop (ThermoScientific). The Geneprint 10 Kit (Promega) was used to co-amplify ten human short tandem repeat loci (TH01, TPOX, vWA, Amelogenin, CSF1PO, D16S539, D7S820, D13S317, D5S818 and D21S11) as per the manufacturer's instructions. The PCR products were ran on a 3500 Genetic Analyzer (Life Technologies). Genemapper software (Life Technologies) was used to interpret the results.

**Result**

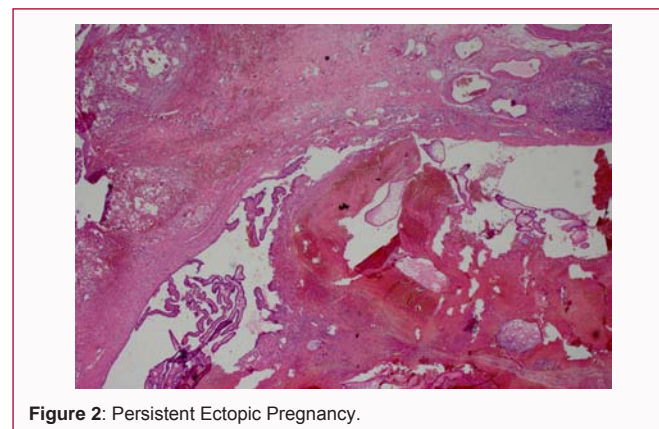
Fetal and maternal DNA from each of the two ectopic pregnancies revealed the same maternal alleles and fetal alleles (Table 2), highly suggestive of the same ectopic female fetus in both cases. The fetus shared at least one allele at each locus with the mother. The results also displayed fetal DNA samples to contain maternal DNA, which was consistent with expectations based on slide review. However, the fetal alleles could be definitely called either by the presence of a novel (paternal) peak or by relative signal intensity of shared alleles (Figure 3). The first fetal sample had less contaminating maternal DNA than the second fetal sample, which was consistent with expectations based on slide review.

**Table 2:** Alleles.

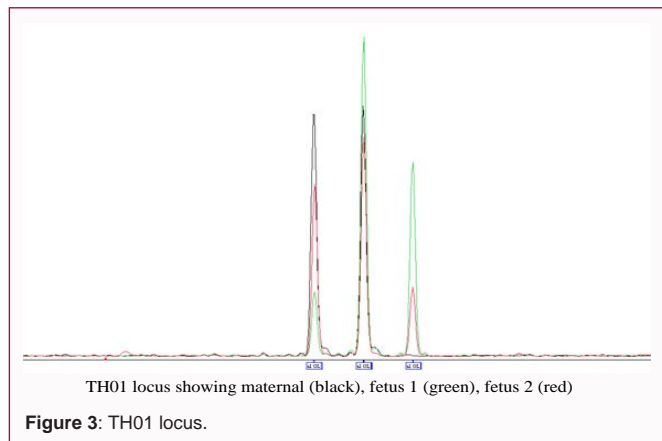
STR Locus	Maternal Alleles	Fetal alleles
TH01	6, 7	7, 8
D21S11	29, 29	29, 30.2
D5S818	11, 11	11, 11
D13S317	9, 12	11, 12
D7S820	11, 12	12, 12
D16S539	10, 11	10, 13
CSF1PO	10, 10	8, 10
Amelogenin	X, X	X, X
vWA	16, 19	17, 19
TPOX	8, 11	9, 11

**Discussion**

Ectopic pregnancies occur in 1-2% of pregnancies and cause 9% of pregnancy related deaths in the United States. As the leading cause of death during the first trimester, prompt diagnosis and treatment of ectopic pregnancies is essential [1-3]. Diagnostic modalities, such as transvaginal ultrasound used in conjunction with hCG levels, are used to confirm the diagnosis and identify the appropriate treatment modality: 1. Expectant management, 2. Medical treatment with methotrexate, or 3. Surgery with either salpingostomy or salpingectomy [1]. As the fallopian tube is preserved, salpingostomy is the preferred surgical choice when the patient wishes to maintain fertility. However, in 3-20% of ectopic pregnancies treated with salpingostomy, failure to remove all trophoblastic tissue resulted in a persistent ectopic pregnancy (PEP) [4,5]. hCG measurements after salpingostomy are vital in the early detection of PEP. Although the optimal frequency and duration for hCG measurements vary amongst different institutions, most protocols recommend monitoring until hCG levels are undetectable. Once hCG levels have normalized, it is assumed that all trophoblastic tissue has been successfully removed and the risk for PEP is minimal. Our patient presented with a hCG level of 571mIU/ml and a salpingostomy was performed on the



**Figure 2:** Persistent Ectopic Pregnancy.



same day (Table 1). The next follow up hCG level was normal at 2 mIU/ml 8 days later, indicating minimal risk for a PEP and follow up measurements were no longer necessary. However, on day 38 after salpingostomy she presented with a hCG of 185 mIU/ml and a ruptured ectopic pregnancy in the same fallopian tube as the prior ectopic pregnancy. Given that the occurrence of a PEP after hCG values normalize post salpingostomy was unexpected, and there have been no reports in the literature of such cases, the possibility of a laboratory error on the day 8 hCG measurement was considered.

Although the hCG sample was no longer available for retesting, review of quality control runs for that day revealed no abnormalities. In our hospital's laboratory, quantitative hCG measurements are performed on a Roche Modular Analytics E170 module by electrochemiluminescence. Quality control runs are performed 3 times a day including samples at normal, high, and very high concentrations. All quality control hCG samples fell within the expected range that day ruling out an analytical error. Pre-analytical errors such as a specimen mix up, which account for 46-68% of laboratory errors, were also investigated [6]. Although the day 8 hCG serum sample was no longer available for testing, a day 8 hematology sample drawn with the suspicious hCG result was available for a delta check. Delta checks compare a lab parameter with low short-term biologic variability, such as MCV, from two different dates. Because variations in values are unlikely to be caused by changes in patient status, a larger than expected deviation can be attributed to errors such as a specimen mix up. The patient's difference in MCV values from day 8 (92.2fL) to day 14 (91.8fL) was a difference of only 0.4%. This difference was compared to the critical difference (CD) which takes into account within-patient biological variation ( $CV_w=1.4$ ) obtained from published data [7] and analytic imprecision ( $CV_a=0.5$ ), derived from analysis of the instrument used:  $CD=2.77 \times (CV_a^2 + CV_w^2)^{1/2}$ . The calculated critical difference of 3.6% was much higher than the negligible 0.4% change seen in our patients MCV value, indicating that a pre-analytical error was highly unlikely.

A second independent ectopic pregnancy was also considered. However, as the products of conception were found in the same tube in similar locations, this possibility seemed unlikely. Furthermore, the patient was placed on depot medroxyprogesterone acetate (DMPA) the day after her salpingostomy. Estimated DMPA failure rate is low (0.3%) and, if given within the first five days of the period cycle, it is immediately effective [8]. As it is an injectable administered by the clinic staff, patient compliance is a non-issue.

To definitively identify that the second ectopic tissue is genetically

identical to the first, and thus a PEP, short tandem repeat (STR) DNA analysis was performed on macro-dissected formalin-fixed, paraffin-embedded tissue from both tissue samples. STR analysis has been used for human cell identification in forensics and in cell-line categorization [9,10]. It provides a robust method of human cell identification with the Geneprint 10 kit having a reported chance of 2 random samples having the same STR fingerprint as  $1:2.92 \times 10^9$ .

Fetal DNA from both of the samples generated identical allelic sizes for each of the STRs examined, highly suggestive of the same ectopic fetus. Amelogenin is incorporated into the STR panel for gender identification. Results from both ectopic tissues indicated the fetus to be female. Given the same father, the likelihood of 2 siblings having the same allele at all 10 loci, including sex, would be  $1:1024$ , minus any homozygous loci the father has.

The occurrence of a tubal PEP, despite normalized hCG values post salpingostomy, has never been described in the literature. Prior studies have elucidated patterns of decline for hCG in PEP occurring after salpingostomy [5,11-14]. Abe characterized hCG clearance curves in 10 patients with PEP after salpingostomy. HCG values steadily increased in one patient postoperatively. The remaining patients showed a transient decrease for 3 days postoperatively, and then a plateauing or increase by day 4-7. No patient had hCG measurements that declined to undetectable levels, although numerical values of the nadir were not provided. The study concluded that if the hCG declined to 14% of the pre-operative level by postoperative day 6, extended, rather than daily, hCG monitoring until normal hCG levels were achieved was recommended [12]. In similar studies that did report the exact nadir value, hCG was found to be 65 and 91 IU/L in Hajenius's cohort, and 23 mIU/ml in Poppe's group [13]. These hCG levels, although low, are not considered normalized or non-detectable and would warrant further intensive hCG monitoring.

A PEP after normalized hCG values post salpingostomy raises the concern that current hCG monitoring protocols may need to be reevaluated. All prior studies have recommended serial measurements until hCG has normalized [5,11-14]. Once all products of conception have been eliminated, the assumption is that there are no longer any trophoblastic cells producing hCG. However, it is plausible that a minute number of trophoblastic cells remained after our patient's salpingostomy. These numbers were low enough for hCG to normalize within 8 days, but sufficient for continued PEP growth seen on day 38. Thus, continued monitoring of hCG may be required beyond the first normalized hCG measurement. Stratification of patients into high versus low risk of PEP after salpingostomy would aid in identifying patients who require intensive hCG monitoring. Kayatas reports that the size of ectopic pregnancy (>3.35 cm) and location (ampullary 0.3%, fimbrial 25% failure rate) were the most important correlates to salpingostomy failure [14]. However, these findings were contradicted by Fujishita et al. [15] who found no correlation with size and location of the ectopic pregnancy. By Kayatas criteria, our patient would be considered low risk for PEP given the location in the ampulla. Levels of preoperative hCG values were also studied. No significant statistical differences between successful versus failed salpingostomy were found by Kayatas. However, Rabsichong et al. [16] commented that a hCG value of >1960 IU/L was significant by multivariate logistic regression analysis, although the failure rate was still low. Another study found a 100% failure rate when hCG was extremely elevated at 10,000 IU/L [15]. Our patient presented with preoperative hCG of only 571mIU/mL and did not meet any

published criteria associated with higher rates of failed salpingostomy.

There has been only one reported instance in which hCG values normalized despite a persistent ectopic pregnancy [17]. Tien describes a case in which a cervical ectopic pregnancy was treated with methotrexate and then followed by serial hCG measurements and transvaginal ultrasound. hCG was undetectable by week 10, but ultrasound imaging showed persistent products of conception present throughout the duration of hCG monitoring that remained relatively unchanged in size. Serial ultrasound evaluation was integral in identifying the persistent ectopic pregnancy in this case. Our patient however had both a negative ultrasound finding and normalized hCG after treatment (Table 1). However, comparing a rare, and more difficult to treat, cervical PEP to our tubal PEP is like comparing apples to oranges.

The unusual scenario of a PEP, despite normalized hCG values and transvaginal ultrasound findings, suggests that extension of hCG monitoring, even after normalization, may be necessary.

## References

1. Barash JH, Buchanan EM, Hillson C. Diagnosis and management of ectopic pregnancy. *Am Fam Physician*. 2014; 90: 34-40.
2. Creanga AA, Shapiro-Mendoza CK, Bish CL, Zane S, Berg CJ, Callaghan WM. Trends in ectopic pregnancy mortality in the United States: 1980-2007. *Obstet Gynecol*. 2011; 117: 837-843.
3. Seeber BE, Barnhart KT. Suspected ectopic pregnancy. *Obstet Gynecol*. 2006; 107: 399-413.
4. Seifer DB, Diamond MP, DeCherney AH. Persistent ectopic pregnancy. *Obstet Gynecol Clin North Am*. 1991; 18: 153-159.
5. Hajenius PJ, Mol F, Mol BW, Bossuyt PM, Ankum WM, van der Veen F. Interventions for tubal ectopic pregnancy. *Cochrane Database Syst Rev*. 2007: CD000324.
6. Hammerling JA. A review of medical errors in laboratory diagnostics and where we are today. *Lab Med*. 2012; 43: 41-44.
7. Westgard QC. c2014. Madison (WI): Westgard QC.
8. Hatcher RA, Trussell J, Stewart FH, Nelson AL, Cates W, Guest F, et al. *Contraceptive Technology*. 18<sup>th</sup> rev. ed. New York: Ardent Media. 2004; 773-845.
9. Butler JM. Genetics and genomics of core short tandem repeat loci used in human identity testing. *J forensic sci*. 2006; 51: 253-265.
10. Ewing MM, McLaren RS, Hebble KD, Ready K, Storts DR, Hooper K. Human Cell Line and Tissue Sample Authentication. *JBT*. 2013; 24: S48.
11. Spandorfer SD, Sawin SW, Benjamin I, Barnhart KT. Postoperative day 1 serum human chorionic gonadotropin level as a predictor of persistent ectopic pregnancy after conservative surgical management. *Fertil Steril*. 1997; 68: 430-434.
12. Abe T, Askira S, Negishi Y, Ichikawa M, Nakai A, Takeshita T. Relevance of declines in serum human chorionic gonadotropin levels to the management of persistent ectopic pregnancy. *J Obstet Gynaeco Res*. 2009; 35: 961-966.
13. Poppe WA, Vandenbussche N. Postoperative day 3 serum human chorionic gonadotropin decline as a predictor of persistent ectopic pregnancy after linear salpingostomy. *Eur J of Obs & Gyn Repr Bio*. 2001; 99: 249-252.
14. Kayatas S, Demirci O, Kumru P, Mahmutoglu D, Saribrahim B, Arinkan SA. Predictive factors for failure of salpingostomy in ectopic pregnancy. *J Obstet Gynaecol Res*. 2014; 40: 453-458.
15. Fujishita A, Khan KN, Kitajima M, Hiraki K, Miura S, Ishimaru T, et al. Re-evaluation of the indication for and limitation of laparoscopic salpingotomy for tubal pregnancy. *Eur J Obstet Gynecol Reprod Biol*. 2008; 137: 210-216.
16. Rabischong B, Larraín D, Pouly JL, Jaffeux P, Aublet-Cuvelier B, Fernandez H. Predicting success of laparoscopic salpingostomy for ectopic pregnancy. *Obstet Gynecol*. 2010; 116: 701-707.
17. Tien SH, Yamamura Y. Cervical Ectopic Pregnancy: Persistence Despite a Serologically Negative  $\beta$ -hCG. A Case Report. *J Reprod Med*. 2015; 60: 257-260.